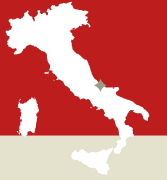

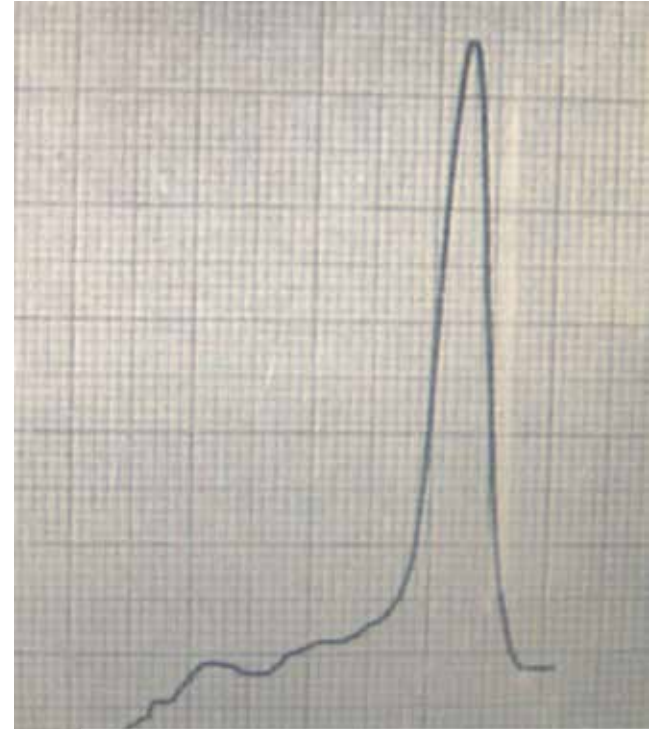
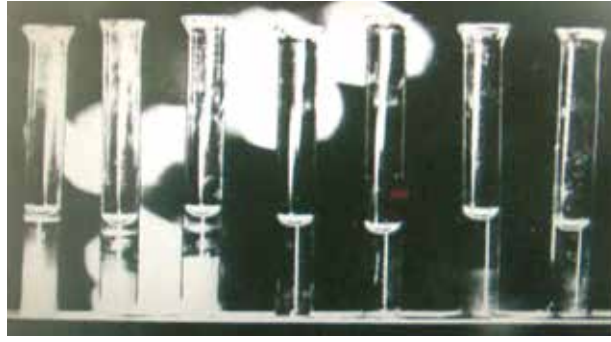
Eucharistic Miracle of LANCIANO

ITALY, 750 A.D

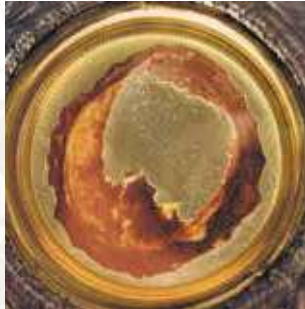2



The Flesh and the Blood of Lanciano therefore are just the same as they would be if they had been drawn that very day from a living being.



Graph of the electrophoresis of the proteins of the Blood of the Miracle. The profile of the protein fractions from the serum could be superimposed on a standard specimen of fresh blood



The flesh consists of part of the myocardium, more precisely of the left ventricle. The arteries and veins can be easily identified, as well as a double, slender branch of the vagus nerve. At the time of the miracle, the flesh was living and then submitted to the law of rigor mortis.

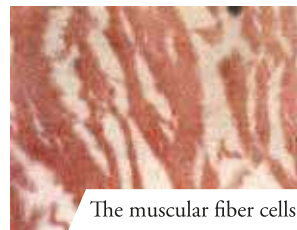The miracle was the object of several official acknowledgements on the part of the ecclesiastical authorities between 1574 and 1886, not to mention most recently, in 1970, when it was subjected to a scientific examination carried out by professors from the University of Siena, which concluded: "The flesh is true human flesh (formed by muscular tissue from the heart); that the blood is true blood (belonging to the same blood type AB as the flesh); that the component substances are those of human tissues, normal and fresh; that the conservation of the flesh and the blood, left in their natural state for twelve centuries and exposed to the influence of atmospheric and biological elements, remains an extraordinary phenomenon" (The Linoli Report 4131971)



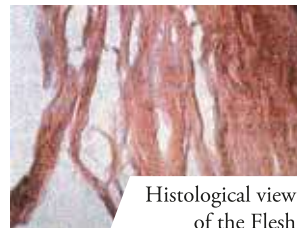
The reliquary from the 18th century containing the Host and the coagulated Blood, gift of the generous citizen Domenico Coli




The 5 clots of Blood as seen with a magnifying glass. In the blood of the Miracle can be recognized all the components present in fresh blood, and the miracle within the miracle, each of the 5 clots of Blood weighs 15.85 grams, which is the identical weight of the 5 clots weighed together !



The muscular fiber cells



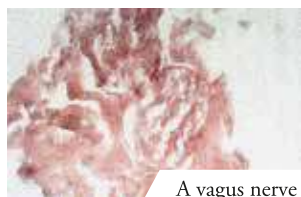
Histological view of the Flesh



The Church of St. Francis was constructed almost 500 years later, in 1258, above the chapel where the miracle took place



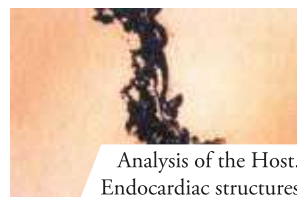
An antique painting depicting the Miracle



A vagus nerve



A small lobe of adipose tissue



Analysis of the Host. Endocardiac structures



Cubical lattice in gold-plated cast iron in which the relics were preserved for almost 266 years, today returned to the Valsecca family chapel



An antique painting depicting the Miracle